

An Unusual Case of Herpes Simplex Viral Encephalitis Following Acute Retinal Necrosis after Administration of a Systemic Steroid

Sang Jin Kim, MD, PhD¹, Se Woong Kang, MD, PhD¹, Eun Yeon Joo, MD, PhD²

Departments of ¹Ophthalmology, ²Neurology, Samsung Medical Center, Sungkyunkwan University School of Medicine, Seoul, Korea

Case Report

Journal of Epilepsy Research
pISSN 2233-6249 / eISSN 2233-6257

Received March 22, 2012

Accepted March 30, 2012

Corresponding author: Eun Yeon Joo
Department of Neurology, Samsung
Medical Center, Sungkyunkwan
University School of Medicine,
81 Irwon-ro, Gangnam-gu, Seoul
135-710, Korea
Tel. +82-2-3410-3597
Fax. +82-2-3410-0052
E-mail; ejoo@skku.edu

Acute retinal necrosis (ARN), a viral retinal disease with poor visual prognosis, following herpes simplex encephalitis (HSE) are uncommonly seen, and there has been no case yet reported of the reverse situation. We herein present the reverse situation, an immune-competent patient with HSE following ARN. A 57-year-old man who had been under steroid therapy for retinal vasculitis the prior two weeks, presented with abrupt confusion and high fever. His cerebrospinal fluid study and brain magnetic resonance imaging revealed typical HSE. Ophthalmic examination and polymerase chain reaction of the vitreous specimen revealed ARN by herpes simplex virus type 2. Intravenous acyclovir treatment improved his encephalitis symptoms and retinal necrosis. This case implies that ARN may be a risk factor for HSE and the virus may reach the brain from the eye. Inappropriate administration of a systemic steroid may exacerbate herpes viral infection in the retina, with subsequent spread to the brain. (2012;2:21-24)

Key words: Acute retinal necrosis syndrome; Herpetic simplex encephalitis; Herpes simplex; Steroids

Acute retinal necrosis (ARN) is a devastating ocular disease with poor visual prognosis and is most often caused by varicella zoster virus (VZV) or herpes simplex virus (HSV)-1 and less frequently by HSV-2 and cytomegalovirus.^{1,2} ARN is characterized by peripheral necrotizing retinitis, retinal arteritis, and a prominent inflammatory reaction in the vitreous and anterior chamber.³ This disease may present several years after a primary infection, or it may occur following systemic herpetic infection. The prevalence of the disease is equal in both genders, and it occurs in the 5th-7th decade of life.⁴ Though the diagnosis of ARN is made clinically in most patients, polymerase chain reaction (PCR) analysis of the aqueous humor or vitreous is known as a confirmative method to detect the causative virus. Cases who presented with unilateral or bilateral ARN following herpes simplex viral encephalitis (HSE) have been uncommonly reported.⁵⁻⁹ However, the reverse situation of HSE following ARN has been reported in one case, who was an immune-suppressed patient.¹⁰ Herein, we present an unusual case of HSE following ARN in an immune-competent patient.

Case Report

A 57-year-old man was referred to Samsung Medical Center with

abrupt confusion, fever, and loss of vision in both eyes. The patient was in his usual state of health until two weeks prior, when he began to develop sudden loss of vision in his right eye. In another hospital, he was diagnosed with retinal vasculitis in his right eye and was prescribed oral prednisolone, 60 mg/day for three days, followed by 120 mg/day for three days. The retinal vasculitis did not respond to oral prednisolone, so he was treated with intravenous methylprednisolone, 1 g/day for five days. Two days after initiation of intravenous methylprednisolone, he complained of decreased vision in his left eye. One week after initiation of intravenous methylprednisolone, he became drowsy and high fever occurred, and he was then referred to Samsung Medical Center. On neurological examination, he was drowsy and confused to time and place orientation. Mini-mental status examination was 18. He consistently complained of severe headache and bilateral ocular pain. However, his extraocular movement did not show any limitation in all directions. Neck stiffness and meningeal irritation sign were not definite. Other focal neurologic deficits were not found.

His brain magnetic resonance imaging (MRI) showed a hyperintense lesion in the left medial temporal and bilateral medial occipital areas on T2-weight images, suggestive of HSE (Fig. 1).

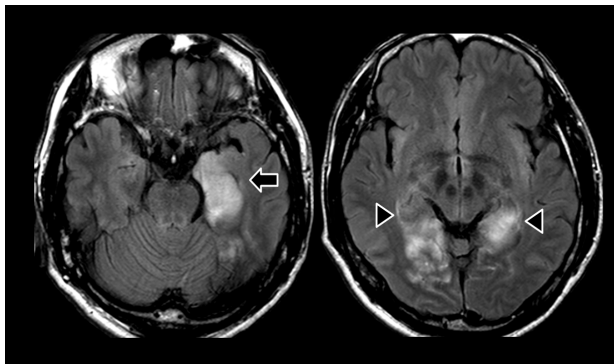


Figure 1. Brain magnetic resonance imaging (MRI) at admission. Fluid-attenuated inversion recovery magnetic image revealed hyperintensity in the left medial temporal (arrow) and bilateral occipital cortices (arrow heads).

Cerebrospinal fluid (CSF) study revealed 11 cells/mL (lymphocytes 90%), low protein (19.3 mg/dL), and normal range glucose concentration (63 mg/dL compared to 110 mg/dL in serum). An empirical antiviral agent (acyclovir 30 mg/kg/d) was administered intravenously. One week later PCR of the CSF was revealed to be positive for HSV-1 DNA. On the night of admission, the patient experienced a generalized tonic-clonic seizure during sleep. His electroencephalography showed sharp waves in left or right anterior temporal areas (F7T7, F8T8 maximum) with a frequency of 1/min and diffuse slow waves. An antiepileptic drug (phenytoin 300 mg/d) was administered and no more epileptic seizure recurred.

On the day of admission, his visual acuity was perception of

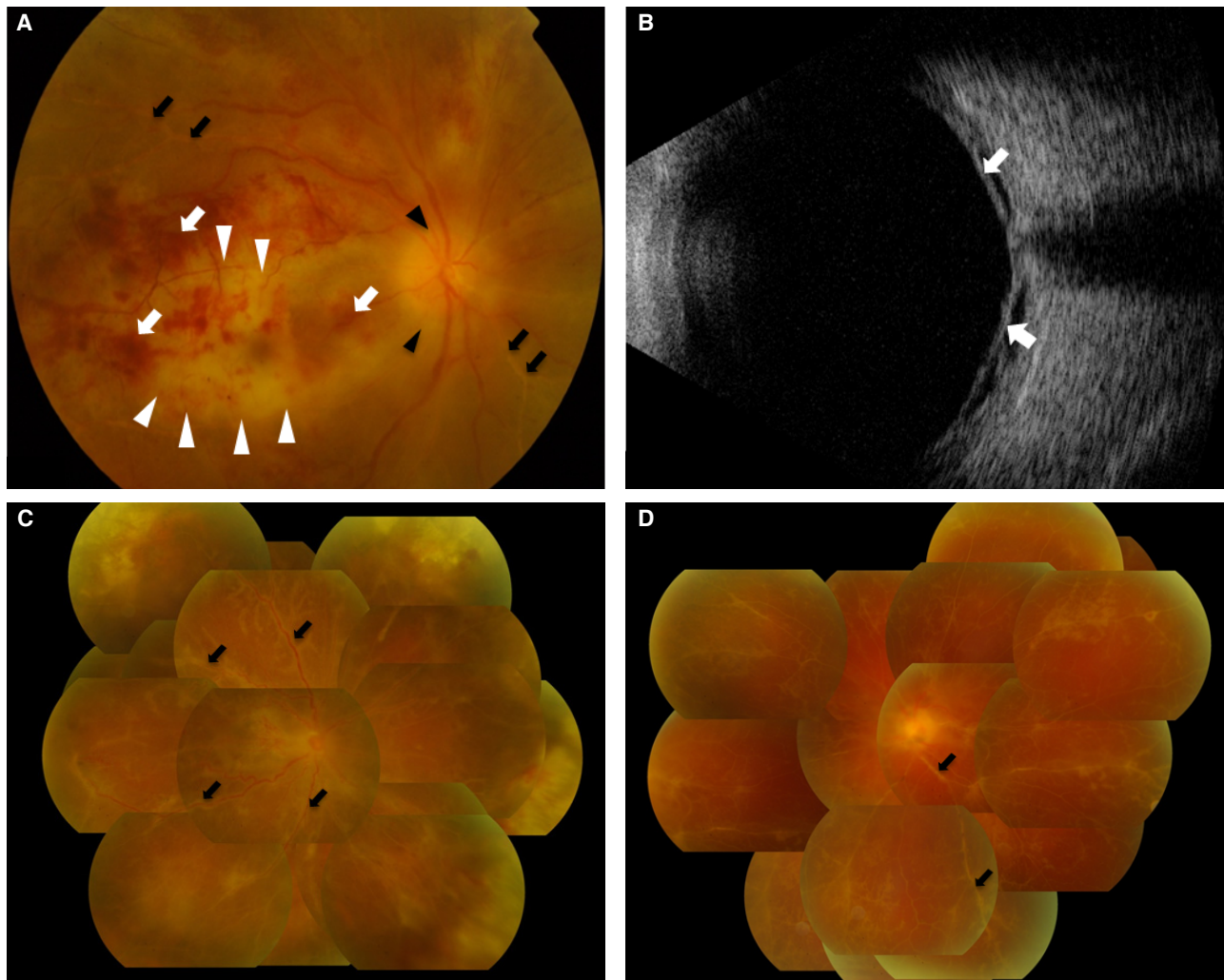


Figure 2. Fundus photographs at initial presentation and after intravenous acyclovir therapy. (A) Initial fundus examination revealed retinal hemorrhage (white arrows), confluent retinal necrosis (white arrow heads), vascular sheathing (black arrows), and optic disc swelling (black arrow heads) in both eyes. (B) Ultrasonography shows retinal detachment (arrows). (C, D). After intravenous acyclovir therapy, retinal necrosis with hemorrhage was decreased, but vascular sheathing (black arrows) and exudative retinal detachment persisted.

light in both eyes. Fundus examination showed retinal hemorrhage, confluent retinal necrosis affecting almost the whole retina, vascular sheathing involving both arterioles and venules, optic disc swelling, and exudative retinal detachment in both eyes (Fig. 2A). Fluorescein angiography revealed multiple vascular occlusions and vascular leakage. Ultrasonography shows retinal detachment in both eyes (Fig. 2B). Infectious retinitis including acute retinal necrosis was suspected, but in terms of the location of necrosis, his clinical features were not typical of ARN. Diagnostic vitrectomy confirmed the presence of HSV-1. Finally, he was diagnosed with ARN with optic neuropathy by HSV-1.

After administration of intravenous acyclovir for 14 days, his systemic symptoms consistent with encephalitis slowly resolved, but his vision was not restored. On follow-up examination, retinal necrosis did not progress, but he still suffered from severe bilateral ocular pain with partial improvement of the exudative retinal detachment (Fig. 2C, D). Thus, intravitreal ganciclovir injection (5,000/0.05 µg/mL) causes pain relief and decreased intraocular inflammation. But his visual acuity could not percept any light. Bilateral rhegmatogenous retinal detachment with optic atrophy was found six weeks later, thus vitrectomy with silicone oil tamponade was done in the right eye.

Discussion

Cases with ARN following HSE have been uncommonly reported,⁵⁻⁹ and to our knowledge, this is the first report of the reverse situation, HSE following ARN, in even an immune-competent patient. ARN associated with HSE is known to be caused by axonal transmission of a reactivated latent virus from the brain to the retina, and retinitis occasionally occurs after the encephalitis. As shown by our patient, opposite direct transmission from the retina to the brain seems to be possible. This is consistent with the finding that herpes virus uses bidirectional fast-axonal transport in neurons.¹¹

ARN usually presents as retinal necrosis with discrete borders located in the peripheral retina, rapid progression, circumferential spread, occlusive vasculopathy with arterial involvement, and a prominent inflammatory reaction in the vitreous and anterior chamber.³ Our patient was initially diagnosed with retinal vasculitis and treated with a high-dose systemic corticosteroid, which was not effective. Corticosteroids are known to affect cellular immunity and may promote viral replication. Intraocular or systemic corticosteroids may induce retinal necrosis in patients with viral infection. Thus, it is

recommended that corticosteroids should be used in combination with antiviral agents or after beginning antiviral therapy.¹² In this patient, the contralateral eye became infected, and HSE occurred during initial corticosteroid therapy without antiviral medication. In cases with an unusual clinical course, especially in retinal vasculitis with arterial involvement, viral uveitis including HSV infection should be suspected. Diagnostic vitrectomy to obtain a vitreous specimen is appropriate in those cases.

In summary, ARN may be a risk factor for HSE, even in an immune-competent patient. The virus may reach the brain from the eye by a trans-axonal route. Systemic steroid therapy may have exacerbated herpes viral infection in the retina, with subsequent spread to the contralateral eye and brain.

References

1. Ganatra JB, Chandler D, Santos C, Kuppermann B, Margolis TP. Viral causes of the acute retinal necrosis syndrome. *Am J Ophthalmol* 2000;129:166-72.
2. Van Gelder RN, Willig JL, Holland GN, Kaplan HJ. Herpes simplex virus type 2 as a cause of acute retinal necrosis syndrome in young patients. *Ophthalmology* 2001;108:869-76.
3. Holland GN. Standard diagnostic criteria for the acute retinal necrosis syndrome. Executive committee of the American Uveitis Society. *Am J Ophthalmol* 1994;117:663-7.
4. Bodaghi B, Rozenberg F, Cassoux N, Fardeau C, LeHoang P. Nonnecrotizing herpetic retinopathies masquerading as severe posterior uveitis. *Ophthalmology* 2003;110:1737-43.
5. Pavesio CE, Conrad DK, McCluskey PJ, Mitchell SM, Towler HM, Lightman S. Delayed acute retinal necrosis after herpetic encephalitis. *Br J Ophthalmol* 1997;81:415-6.
6. Vandercam T, Hintzen RQ, De Boer JH, Van der Lelij A. Herpetic encephalitis is a risk factor for acute retinal necrosis. *Neurology* 2008;71:1268-74.
7. Kianersi F, Masjedi A, Ghanbari H. Acute Retinal Necrosis after Herpetic Encephalitis. *Case Rep Ophthalmol* 2010;1:85-9.
8. Perry JD, Gikin CA, Miller NR, Kerr DA. Herpes simplex encephalitis and bilateral acute retinal necrosis syndrome after craniotomy. *Am J Ophthalmol* 1998;126:456-60.
9. Klein A, Lefebvre P. Three consecutive episodes of acute retinal necrosis due to herpes simplex-1 over twelve years following herpetic encephalitis. *Ocul Immunol Inflamm* 2007;15:411-3.
10. Wittles KN, Goold LA, Gilhotra JS. Herpes simplex encephalitis presenting after steroid treatment of panuveitis. *Med J Aust* 2011;195:87-8.
11. Smith GA, Gross SP, Enquist LW. Herpesviruses use bidirectional fast-axonal transport to spread in sensory neurons. *Proc Natl Acad Sci*

USA 2001;98:3466-70.

12. Tibbetts MD, Shah CP, Young LH, Duker JS, Maguire JI, Morley MG.

Treatment of acute retinal necrosis. *Ophthalmology* 2010;117:818-24.